Khon Kaen University

Gram negative bacilli in skin infection

PARAMA BUDMALA, MD.
CLINICAL PATHOLOGIST
DIVISION OF MICROBIOLOGY & IMMUNOLOGY
PARABUD@KKU.AC.TH

Khon Kaen University

Gram positive bacilli

PARAMA BUDMALA, MD.
CLINICAL PATHOLOGIST
DIVISION OF MICROBIOLOGY & IMMUNOLOGY
PARABUD@KKU.AC.TH

Bacterial skin infection

Objectives

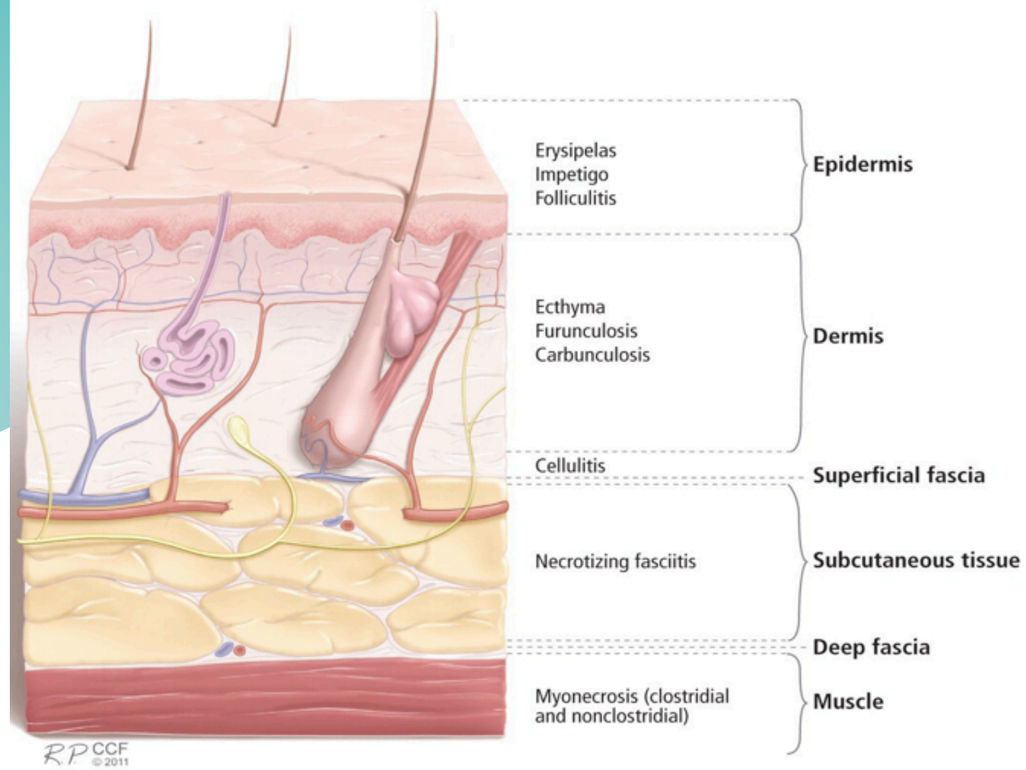

1

- **Gram positive bacilli**
  - ***Bacillus anthracis***
- **Gram negative bacilli**
  - *Pseudomonas aeruginosa*
  - *Burkholderia pseudomallei*
  - *Vibrio vulnificus*
  - *Aeromonas hydrophila*

2

Concept for medical doctor

- Pathogen: Pathogenesis, virulence factor
- Clinical manifestation: history + physical examination
- Diagnosis criteria: clinical +/- laboratory
- Treatment and prevention

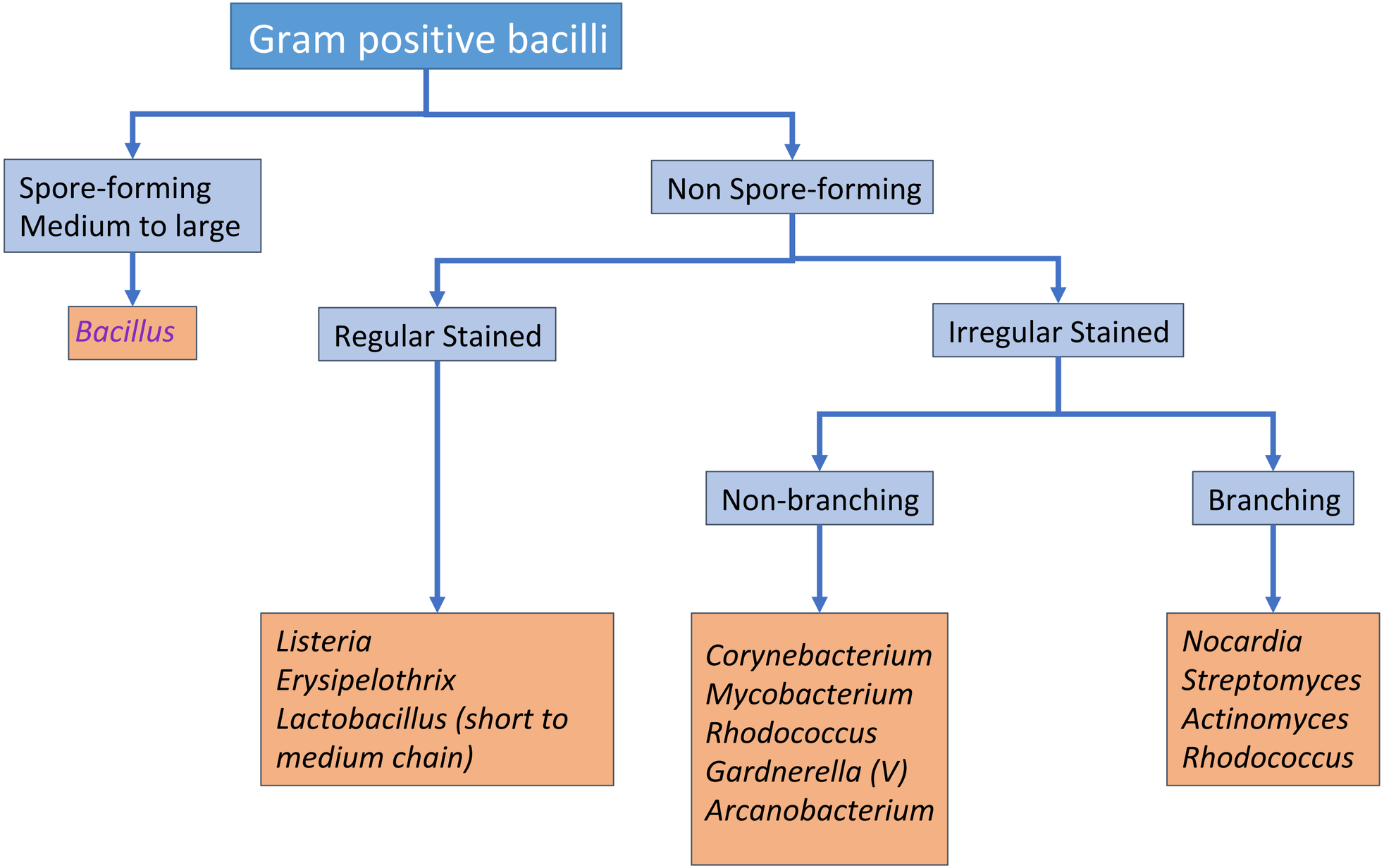
Gram positive bacilli
Spore-forming
Medium to large
Bacillus
Non Spore-forming
Regular Stained
Irregular Stained
Non-branching
Branching
Listeria
Erysipelothrix
Lactobacillus (short to medium chain)
Corynebacterium
Mycobacterium
Rhodococcus
Gardnerella (V)
Arcanobacterium
Nocardia
Streptomyces
Actinomyces
Rhodococcus

Bacillus spp.

Species

- *Bacillus cereus:* recooked rice and grain
- *Bacillus subtilis:* non-pathogenic in soil, water
- *Bacillus licheniformis: Dairy product*

Clinical significance

- Foodborne illness
  - Food poisoning

Diagnosis

- History taking

Treatment

- Supportive

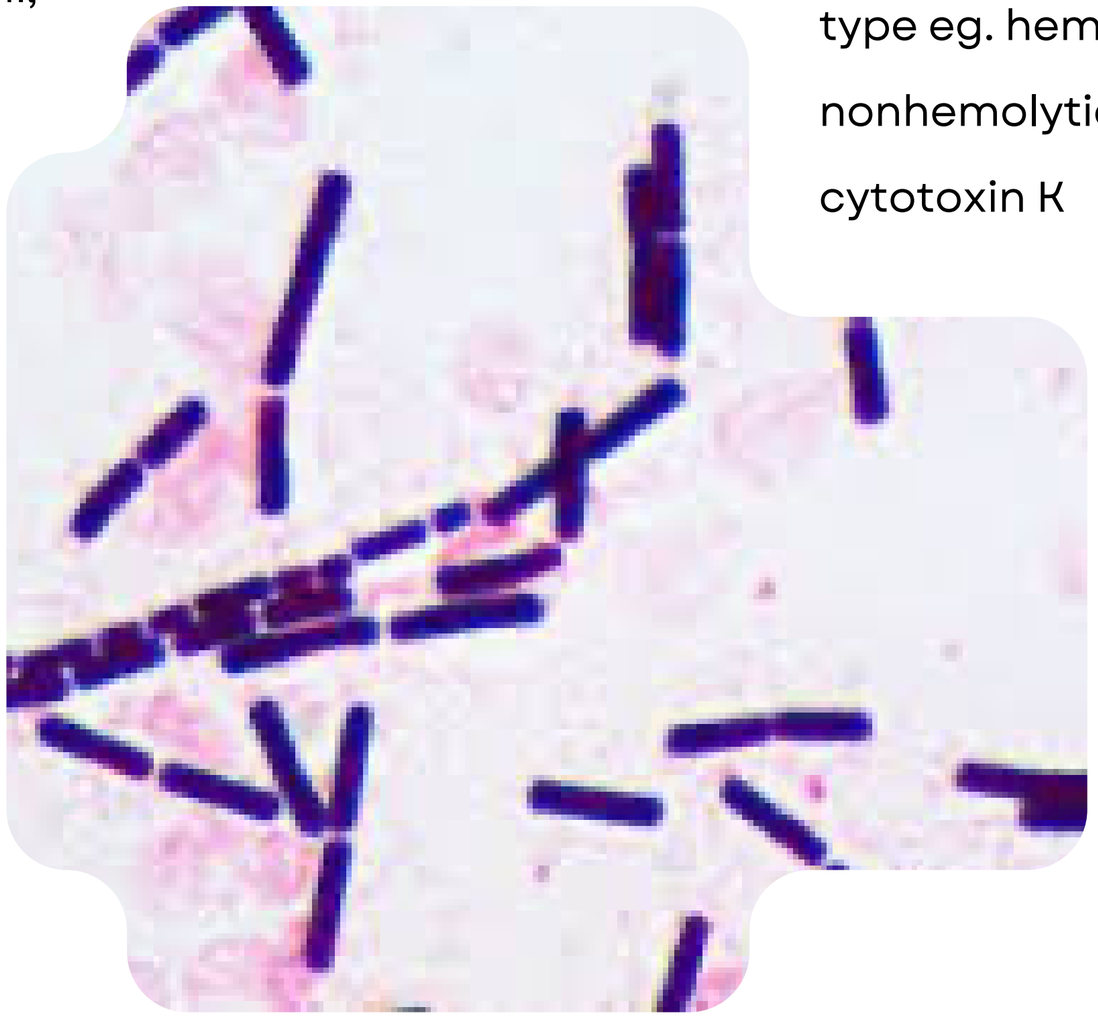

Virulence factor

- Heat,acid-stable toxin (cereulide), emetic type
- Heat-labile Enterotoxin, diarrheal type eg. hemolysin BL (HBL), nonhemolytic enterotoxin (NHE), and cytotoxin K

Bacillus anthracis

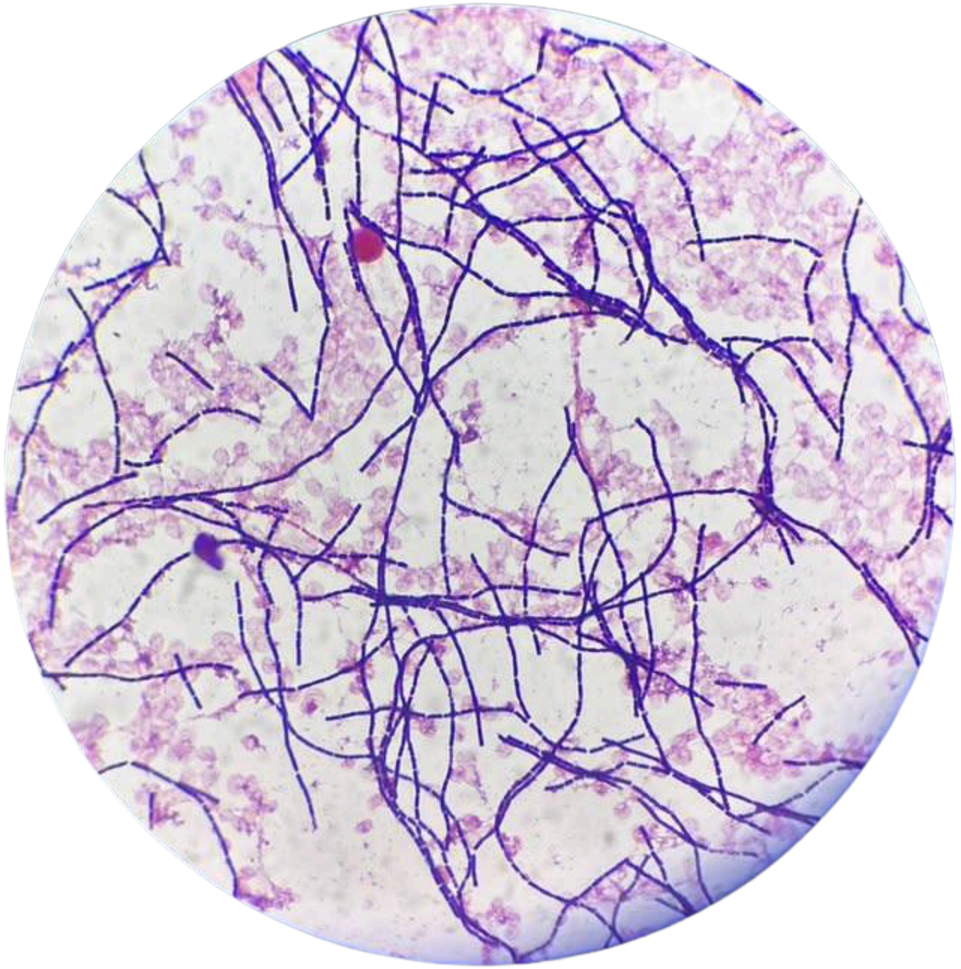

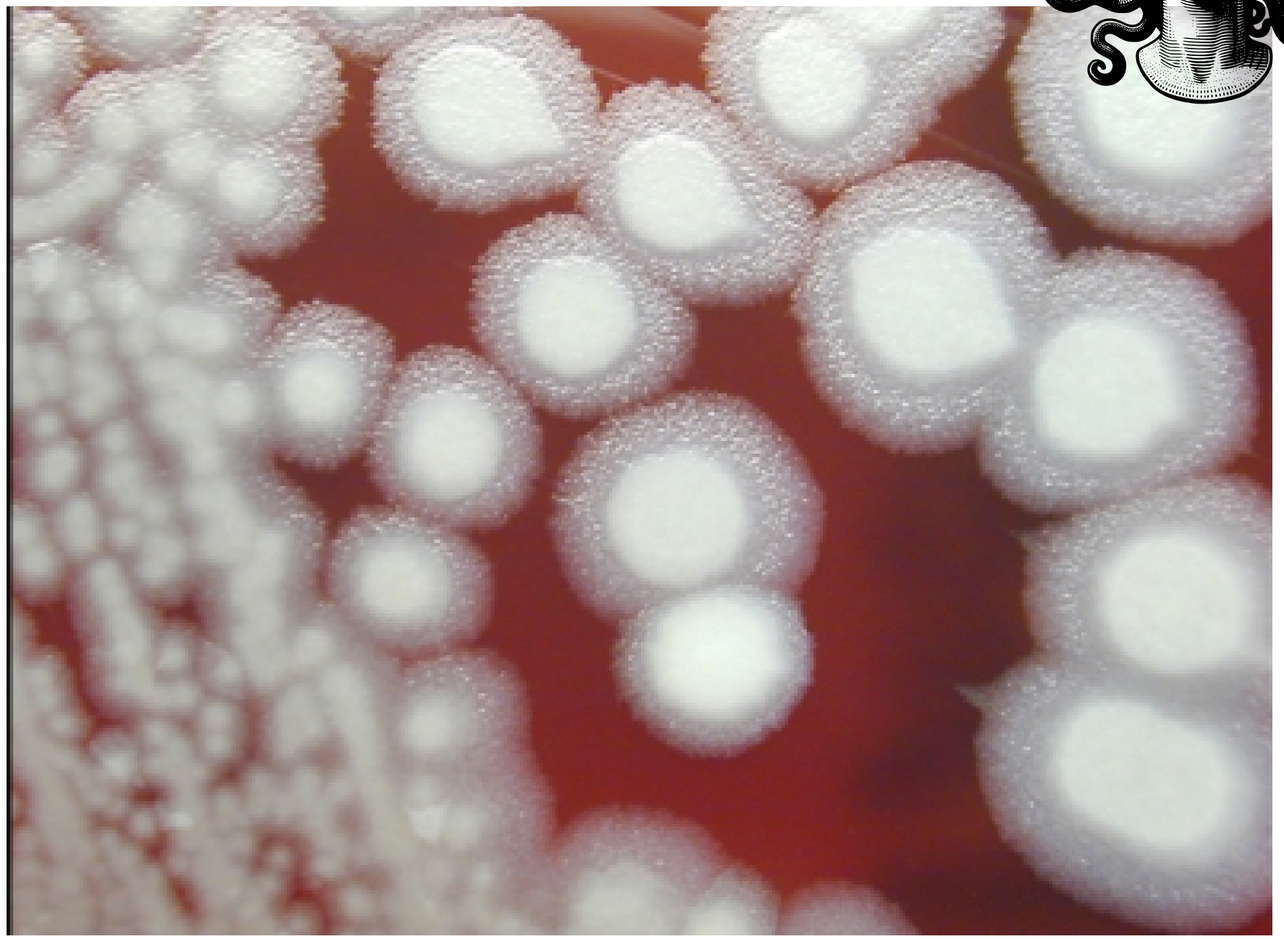

Medusa head colony

Bacillus anthracis

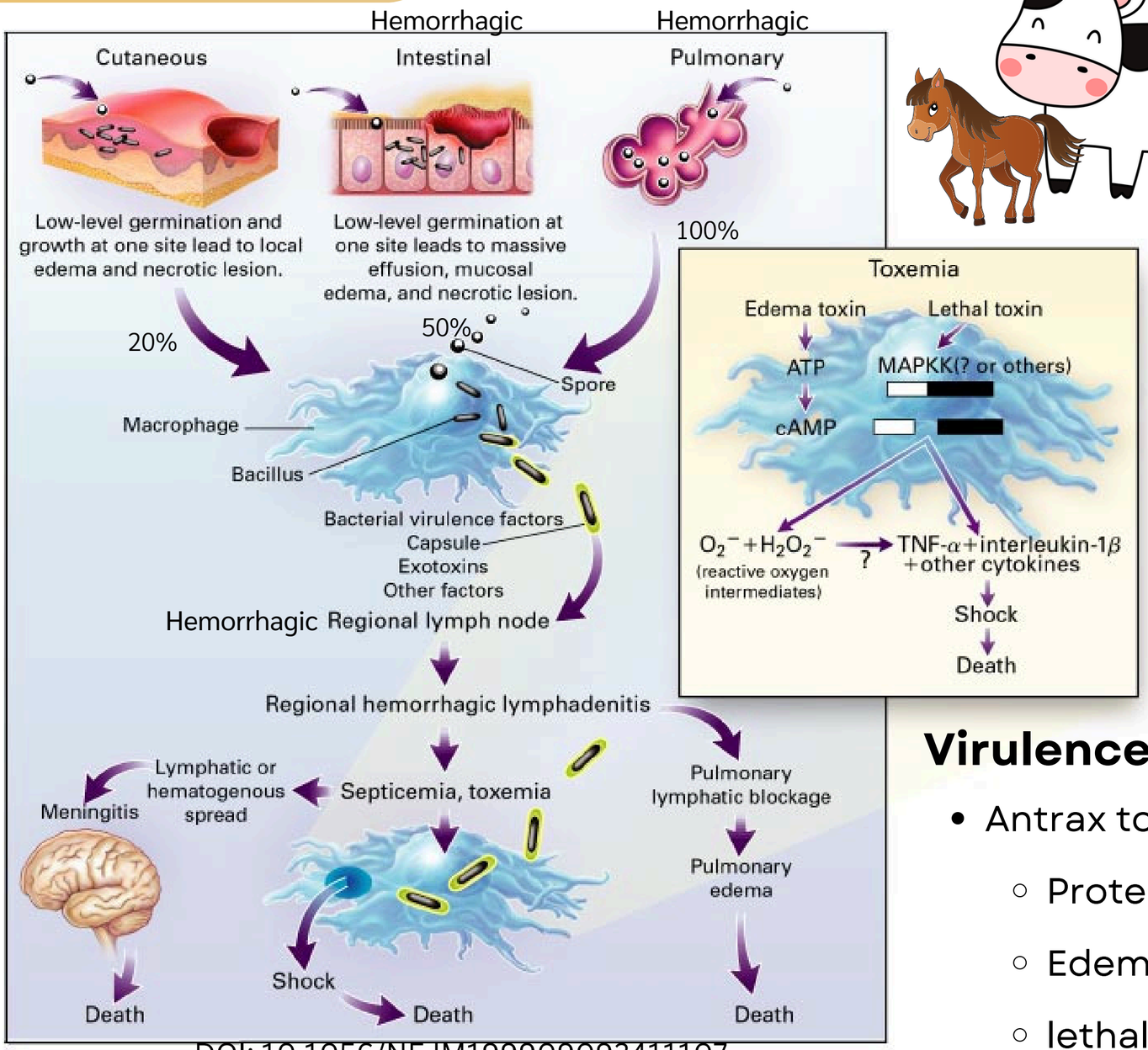

DOI: 10.1056/NEJM199909093411107





Treatment

- Ciprofloxacin
  - Cutaneous: 7-10 days
  - Others: 60 days

Virulence factor

- Antrax toxin
  - Protective antigen
  - Edema toxin
  - lethal toxin

A

B

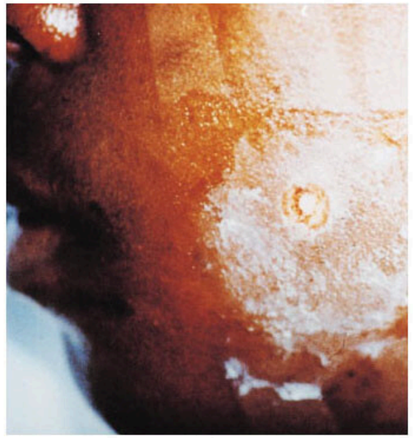

C

D

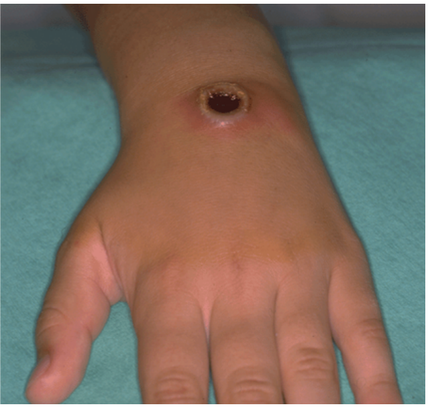

Cutaneous anthrax
DDx Ricketsial eschar

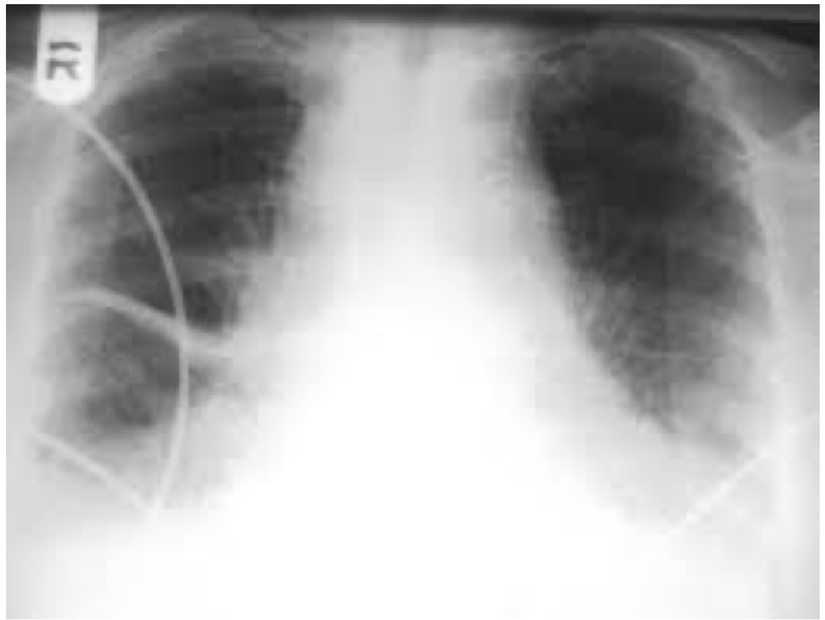

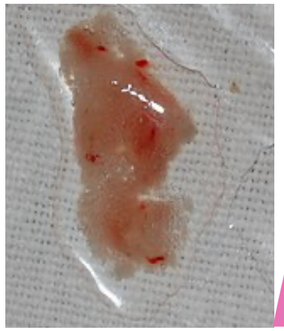

- Flu-like syndrome
- Hemoptysis, chest pain
- Mediastinitis/Hypoxia/ Dyspnea
- Lymphadenopathy

Pulmonary anthrax
(woolsorter's disease)

GastroIntestinal anthrax

Bacterial skin infection

Objectives

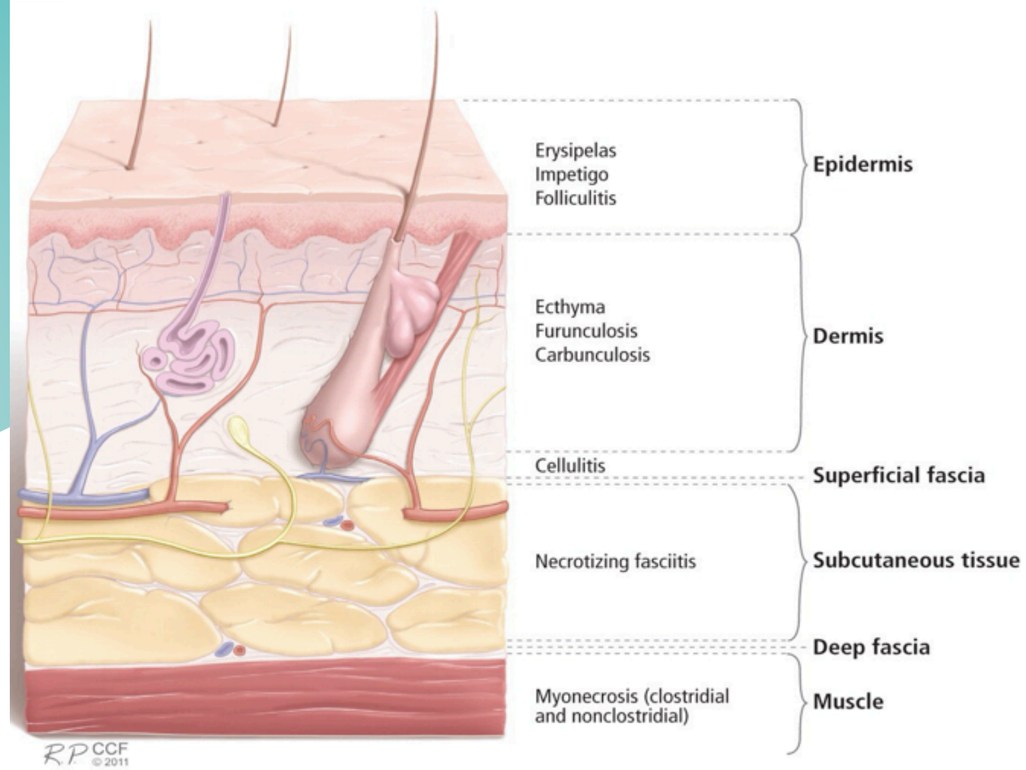

1

- **Gram positive bacilli**
  - ***Bacillus anthracis***
- **Gram negative bacilli**
  - *Pseudomonas aeruginosa*
  - *Burkholderia pseudomallei*
  - *Vibrio vulnificus*
  - *Aeromonas hydrophila*

2

Concept for medical doctor

- Pathogen: Pathogenesis, virulence factor
- Clinical manifestation: history + physical examination
- Diagnosis criteria: clinical +/- laboratory
- Treatment and prevention

Aeriobic

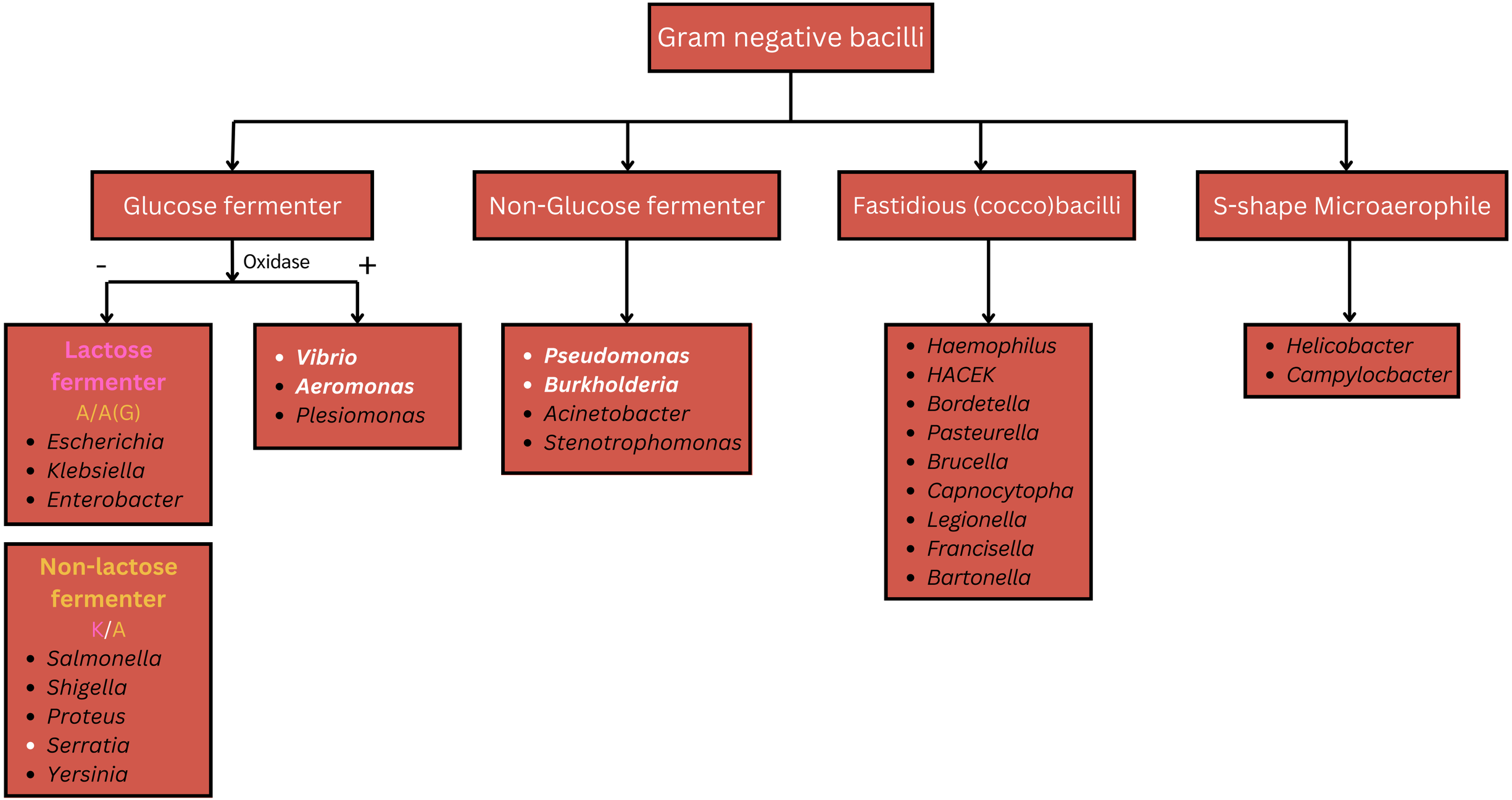
Gram negative bacilli
Glucose fermenter
Non-Glucose fermenter
Fastidious (cocco)bacilli
S-shape Microaerophile
Oxidase
-
+
Lactose fermenter
A/A(G)
• Escherichia
• Klebsiella
• Enterobacter
Non-lactose fermenter
K/A
• Salmonella
• Shigella
• Proteus
• Serratia
• Yersinia
• Vibrio
• Aeromonas
• Plesiomonas
• Pseudomonas
• Burkholderia
• Acinetobacter
• Stenotrophomonas
• Haemophilus
• HACEK
• Bordetella
• Pasteurella
• Brucella
• Capnocytopha
• Legionella
• Francisella
• Bartonella
• Helicobacter
• Campylocbacter

	Morphology	Oxidase	10% Glucose	10% Lactose
Pseudomonas aeruginosa	Slender bacilli	+	A	K
Burkholderia pseudomallei	Safety pin	+	A	A
Acinetobacter baumannii	Coccobacilli (pair)	-	A	A
Stenotrophomonas maltophilia	Bacilli	-	K	K

Pseudomonas aeruginosa

- Gram negative bacilli (slender shaped)
- Green pigmented colony
- Grape-like odor
- Nosocomial > community-acquired
  - Respiratory tract infection
  - UTI
  - Sepsis
  - Otitis externa
  - Keratitis
  - Cellullitis
  - Necrotizing Fasciitis

All systems

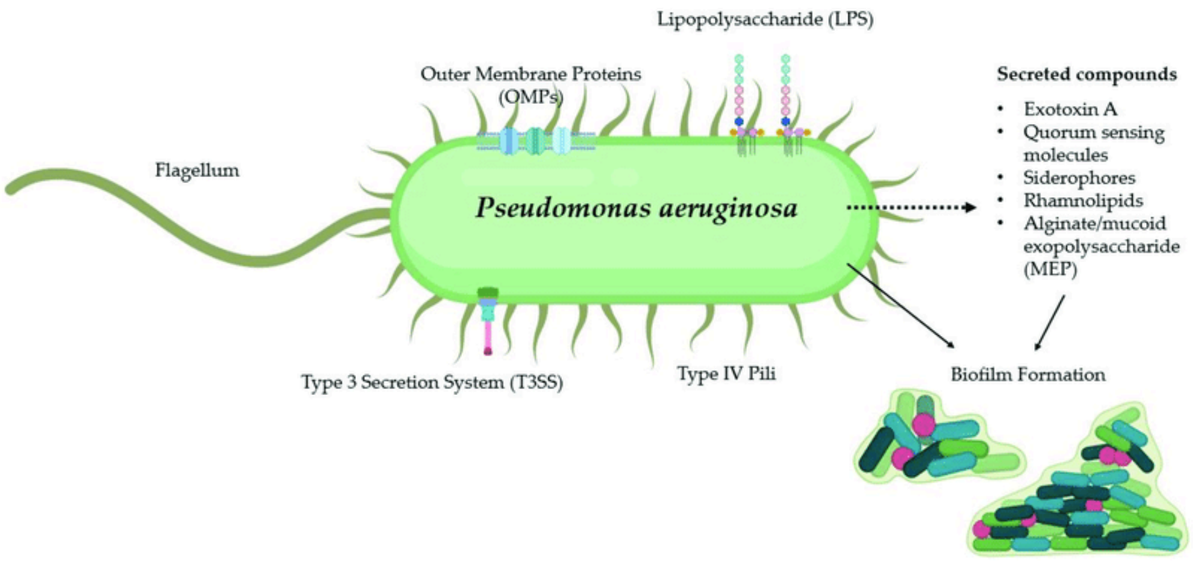

DOI:10.3390/vaccines10071100

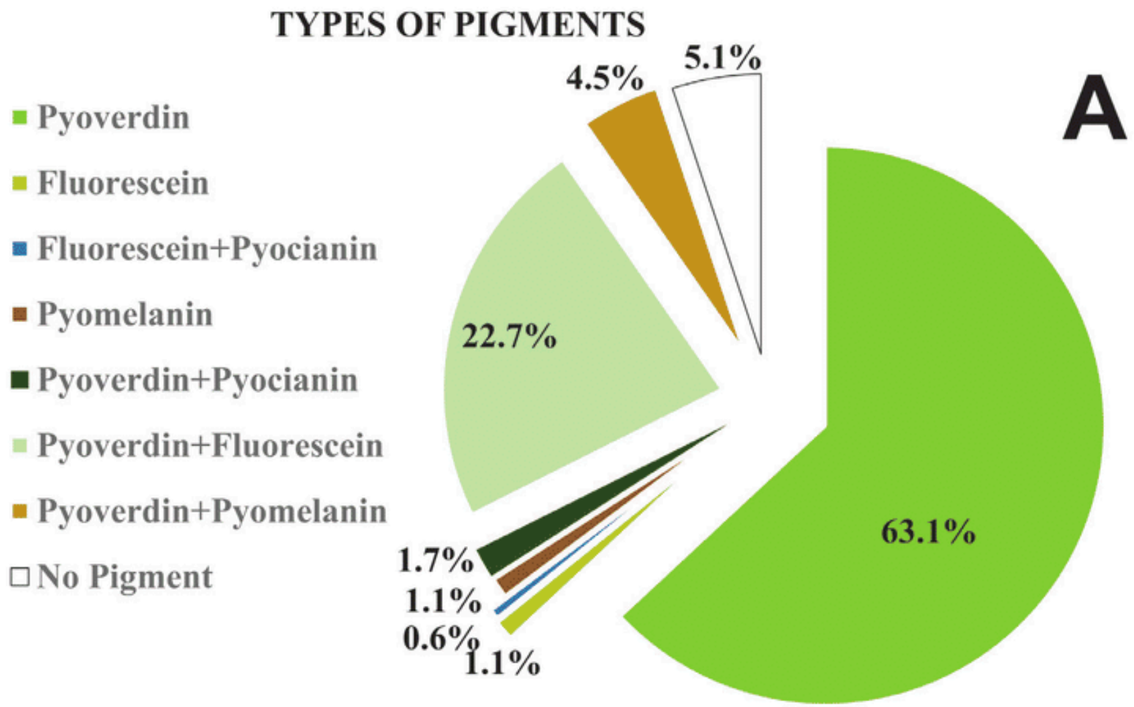

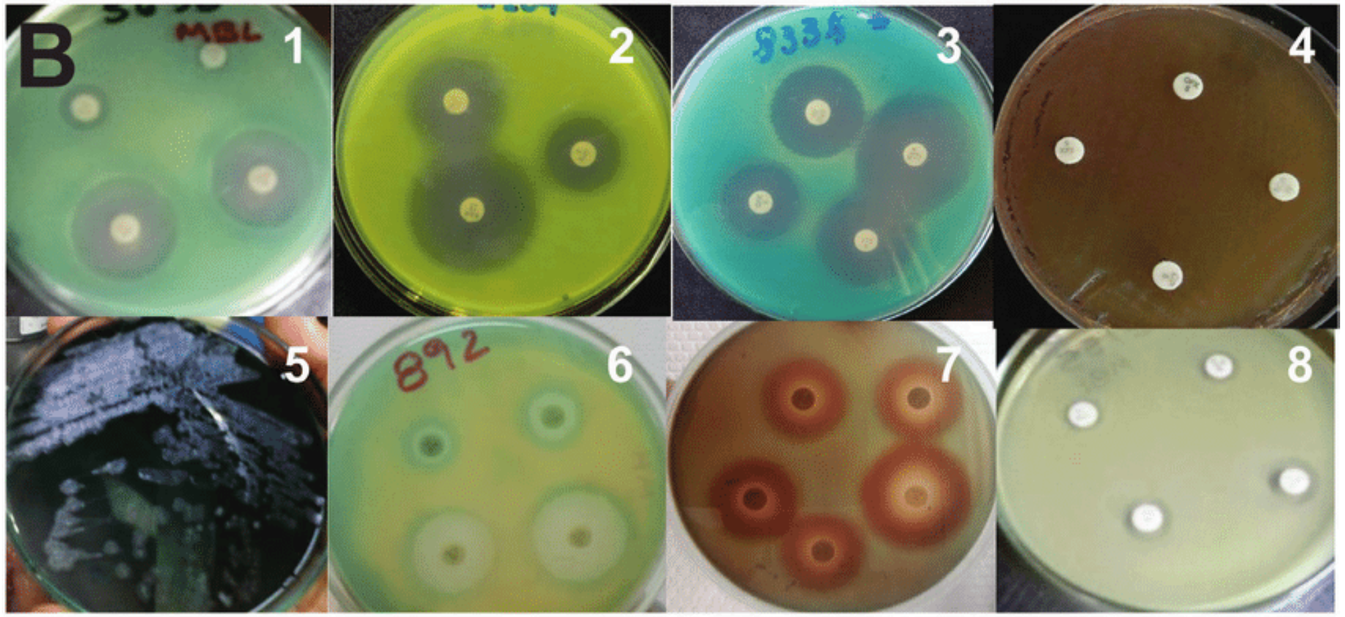

A)

- Examples of different pigments and pigment combinations produced in Mueller-Hinton agar with antibiotics;

B)

- 1: **pyoverdine**,
- 2: fluorescein,
- 3: fluorescein + **pyocyanin,**
- 4: pyomelanin,
- 5: pyoverdine + pyocyanin,
- 6: pyoverdine + fluorescein,
- 7: pyoverdine + pyomelanin,
- 8: no pigment.

DOI:10.1590/S1678-9946201961020

Ecthyma gangrenosum

Clinical significance

- Crusted sores beneath which ulcers

Pathogen

- *Pseudomonas aeruginosa*
- *Etc. E. coli, K. pneumoniae and Candida spp.*

Pathogenesis

- Pseudomonas septicemia
- Invasion of the walls of arteries and veins leading to vascular necrosis (painless)

Risk factor

- immunocompromised
- Burns, ICU

Diagnosis

- Clinical diagnosis
- Blood culture

Treatment

- Ceftazidime iv

(antipseudomonal penicillins)

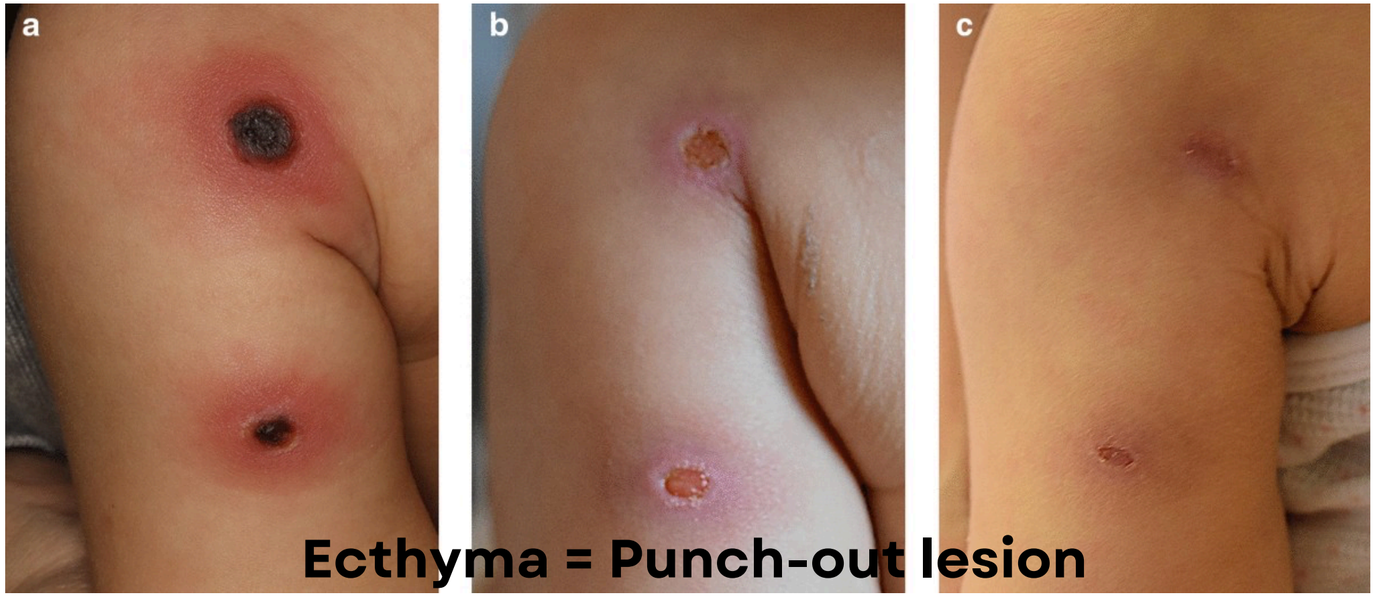

Ecthyma = Punch-out lesion

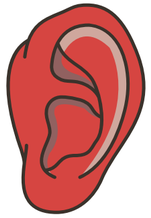

Malignant (necrotizing) Otitis externa

Risk factor

- Eldery
- DM

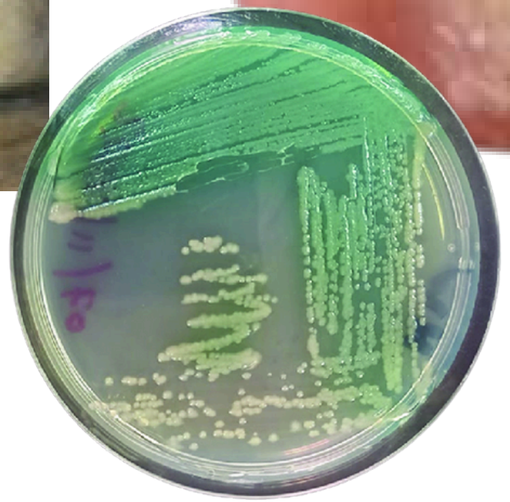

Pseudomonas aeruginosa

Treatment

- Ciprofloxacin
- Steroid

Anti-pseudomonal ATB

CAP TAP For Pseudo

	Drug/Class
C	Cefepime / Ceftazidime (Cephalosporins), Carbapenam except ertapenam
A	Aztreonam
P	Piperacillin–tazobactam
T	Ticarcillin
A	Aminoglycosides except Streptomycin
P	Polymyxins
F	Fluoroquinolones (Cipro, Levo)

Burkholderia pseudomallei

Risk factor

- Soil, water in North-East Thailand
- Skin eruption, wound
- Inhalation of dust
- Immunocompromise host :
  - DM,
  - CKD,
  - Thalassemia,

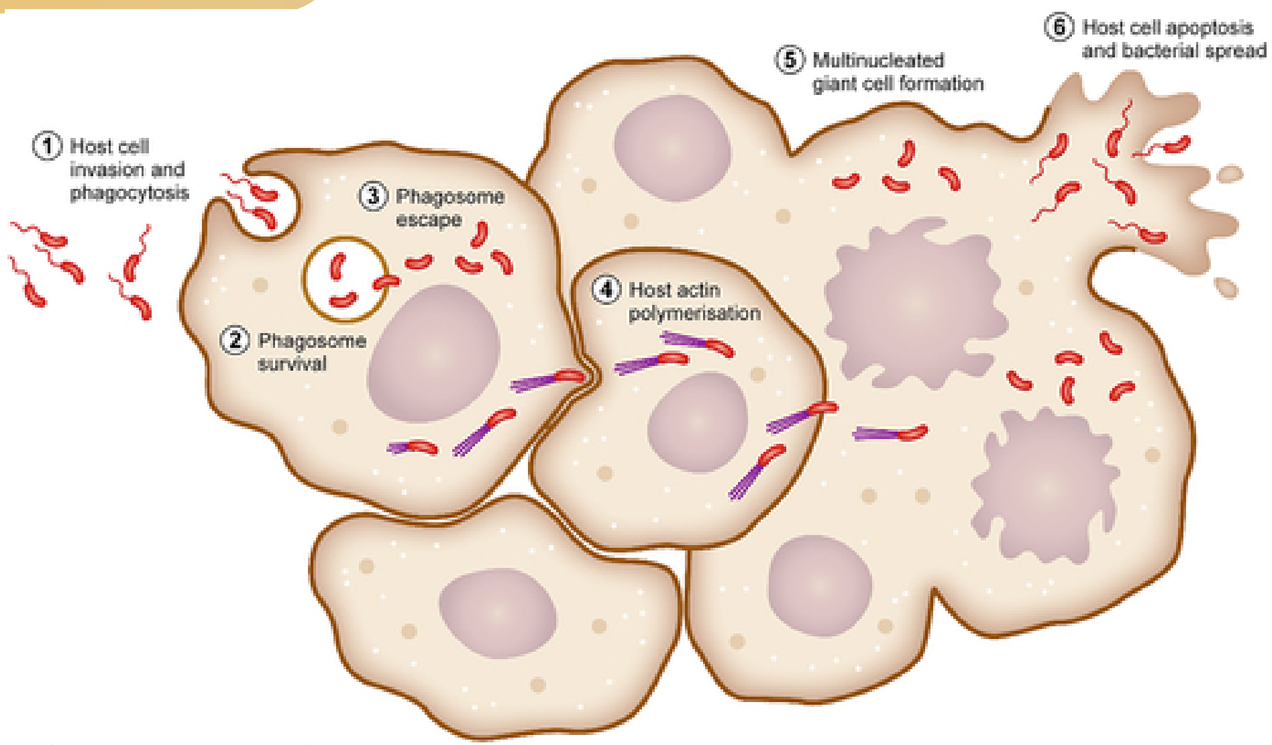

Virulence factor

- T3SS, T6SS
- LPS
- Exotoxin +Extracellular enzymes; dermatonecrotic toxin
- Hemolysin?
- Mortality enhancing polypeptide?
- Iron-acquisition : siderophore (malleobactin)

https://doi.org/10.1080/21505594.2022.2139063

Burkholderia pseudomallei

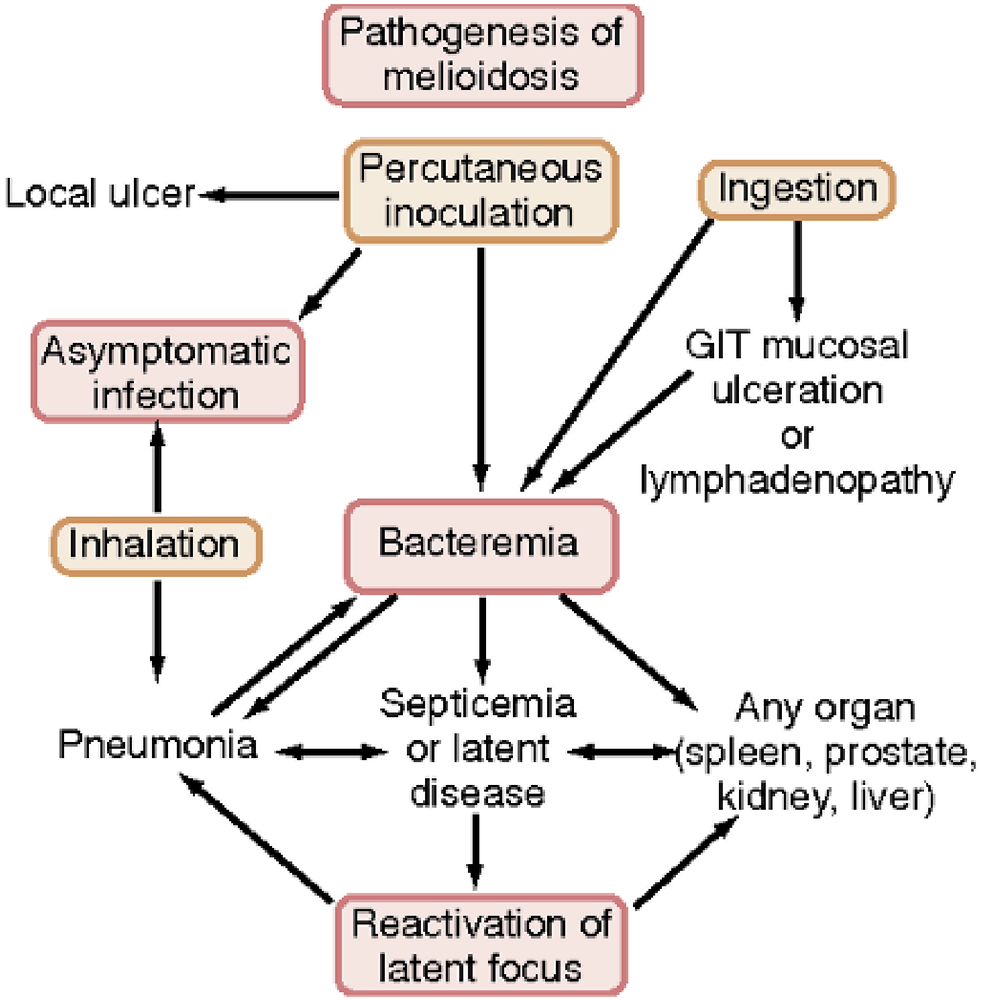

Figure 221-1 **Natural history of infection with *Burkholderia pseudomallei*.** GIT, gastrointestinal tract.

https://doi.org/10.1007/s00284-022-03103-0

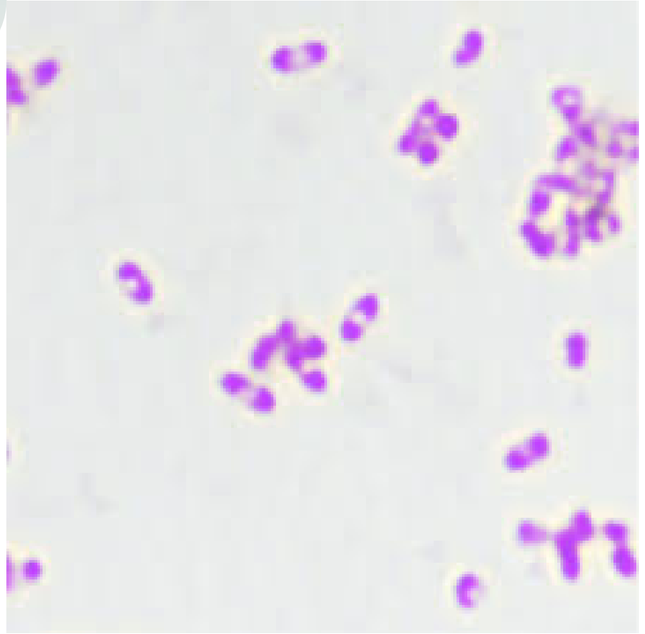

48-72hrs

- Earthy/Musty odor

- **Suppurative Parotitis**
  - No U/D, No septicemia, prior Tx as *S. aueus*

- **Pneumonia**
- **Liver abscess**

Burkholderia pseudomallei

Laboratory diagnosis

- Culture: Pus, Hemoculture
- Serology diagnosis:
  - Indirect Hemagglutination (IHA): Antibody
  - Lateral flow assay (LFA): Antigen
- Molecular diagnosis: PCR

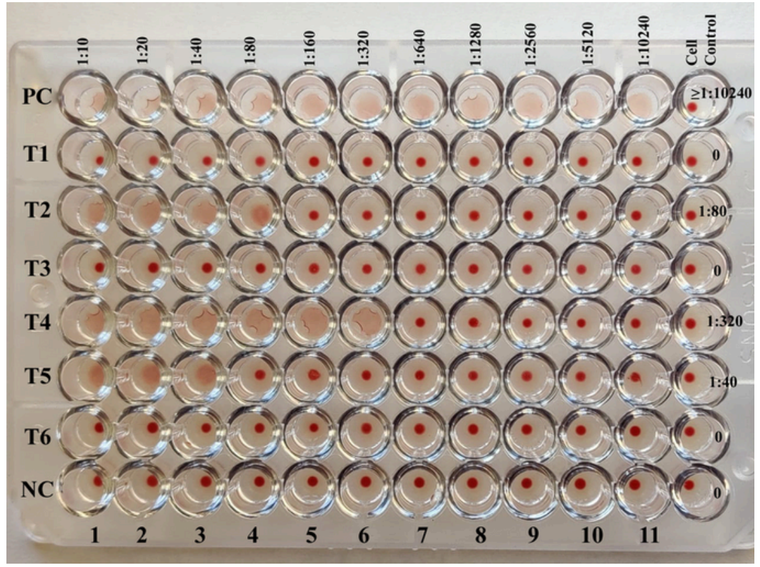

IHA

Active Melioidosis Detect™ (LFA)

IHA Titer	Interpretation (in Thailand)
<1:40	Usually considered negative
≥1:160	May support diagnosis in symptomatic patients
≥1:640 or rising titer	Strongly suggestive of active infection, especially with clinical signs
Stable high titer	May reflect previous exposure, not necessarily active disease

- single high titer is not diagnostic in endemic areas. Seroconversion or a fourfold rising
- Up to 60% of healthy adults may have IHA titers ≥1:40

Treatment

- Induction (10 – 14 days)
  - Ceftazidime 2 g IV q 8 hr
- Maintenance (20 weeks)
  - Cotrimoxazole (80/400) 2 x 2 or
  - Amoxiclav (1 g) 2 x 2

Vibrio vulnificus

Risk factors

- After trauma and exposure to marine animals
- Consumed raw oysters within 7 days

Clinical significance

- Sudden onset of fever and chills,
- Cellulitis or NF (Hemorrhagic bleb)
- Mimic gas gangrene wound
- Septicemia - 50% death
- Diarrhea and Vomiting (less)

Treatment and prevention

- 3rd gen cephalosporin IV
- Debridement

Virulence factor

- Capsule
- Hemolysins and Cytolysins:
- Metalloproteases
- Siderophores



Necrotiziing Fasciitis (Hemorrhagic bleb)

Aeromonas spp.

Species

- *Aeromonas hydrophila* - wound
- *Aeromonas dhakensis* - formly hydrophila
- *Aeromonas caviae* - GI
- *Aeromonas veronii* - wound/GI- leech

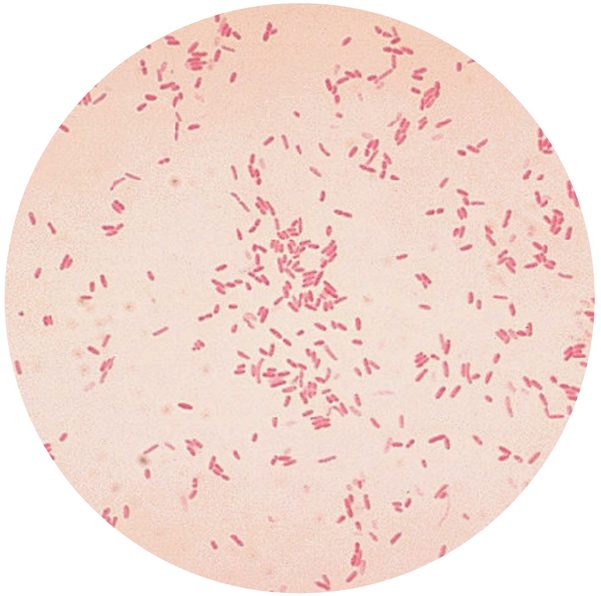

Risk factor

- *Contact or consumption contaminated fresh water*

Clinical significance

- Gastroenteritis (self limiting)
- Cellulitis to necrotizing fasciitis.
- Bacteremia and Sepsis

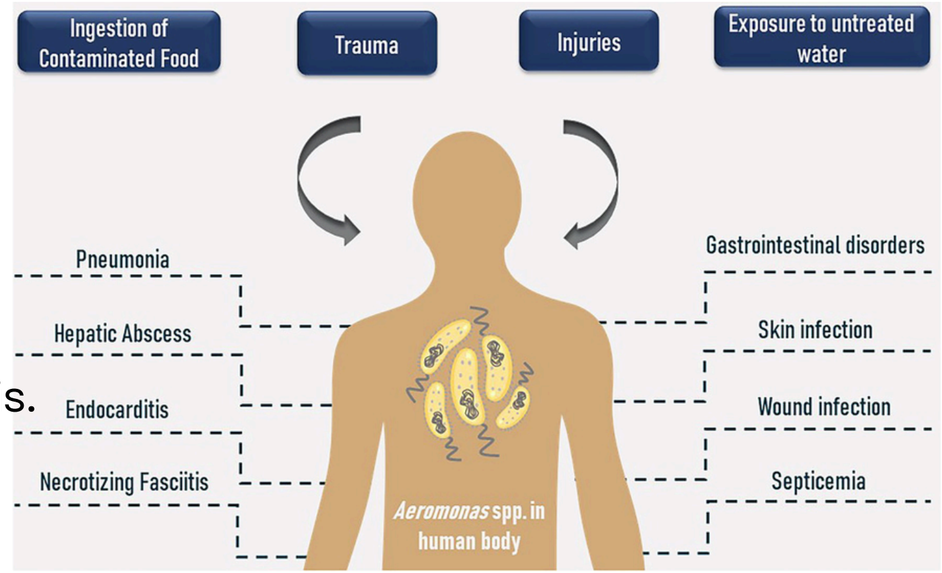

Virulence factor

- Enterotoxins and Cytotoxins
- Hemolysins.
- Adhesins
- Type III Secretion System (T3SS)

Treatment

- Supportive
- Ciprofloxacin or Ceftriaxone
- Debridement

Necrotizing fasciitis

Clinical significance

- flesh-eating disease, rapid progression

Pathogen

- Type I (Polymicrobial) 80%; aerobic and anaerobic
- Type II; *S. pyogenes*, *S. aureus*
- Type III; *V. vulnificus*, *A. hydrophila*
- Type IV; fungus *eg*, *Candida spp.*

Pathogenesis

- Rapid Bacterial Proliferation
- Vascular thrombosis,
- Tissue Ischemia and Necrosis
- Systemic Toxicity; Multi-organ failure

Diagnosis

- Clinical diagnosis, Imaging, Blood culture
- Pus, Tissue Gram stain, culture

Treatment

- Surgical Debridement
- broad-spectrum intravenous antibiotics

Khon Kaen University

Thank You

Any questions?

PARABUD@KKU.AC.TH